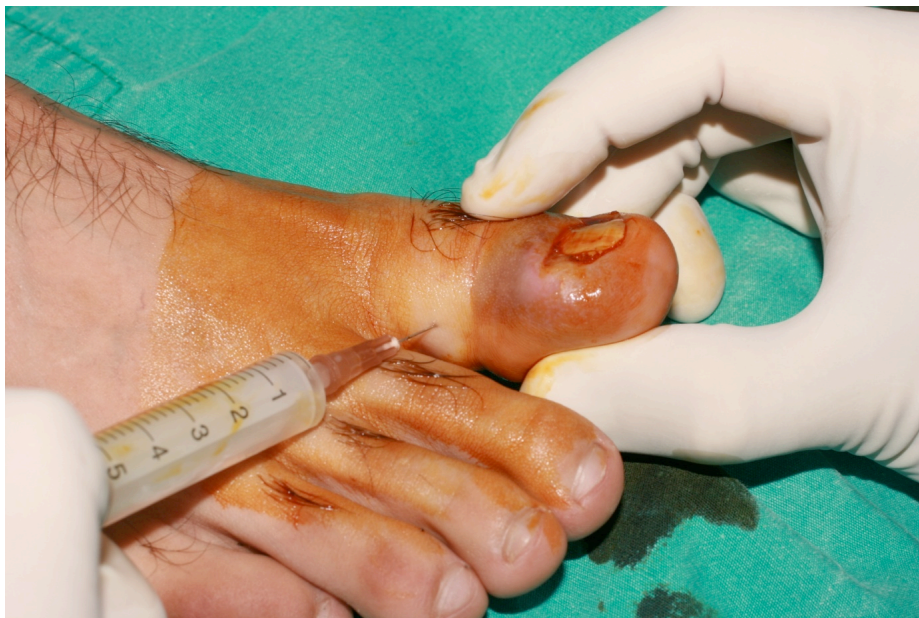

Online Supplementary Material

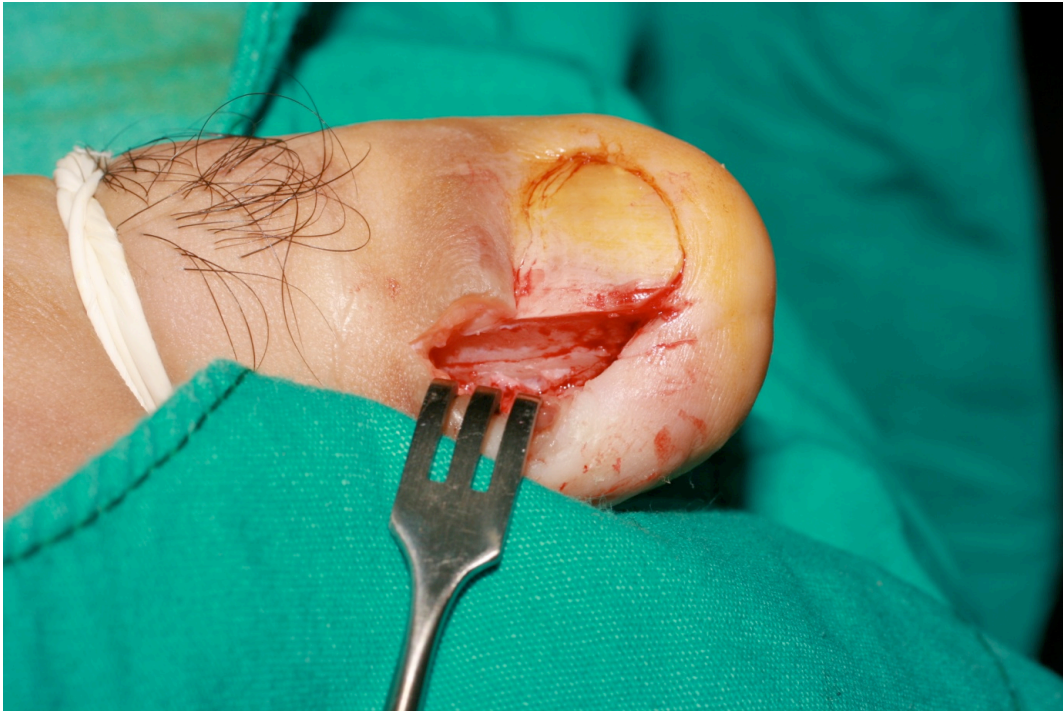Karaca N, Dereli T. Treatment of ingrown toenail with proximolateral matrix partial excision and matrix phenolization. *Ann Fam Med*. 2012;10(6):556-559.

<http://www.annfammed.org/content/full/10/6/556>

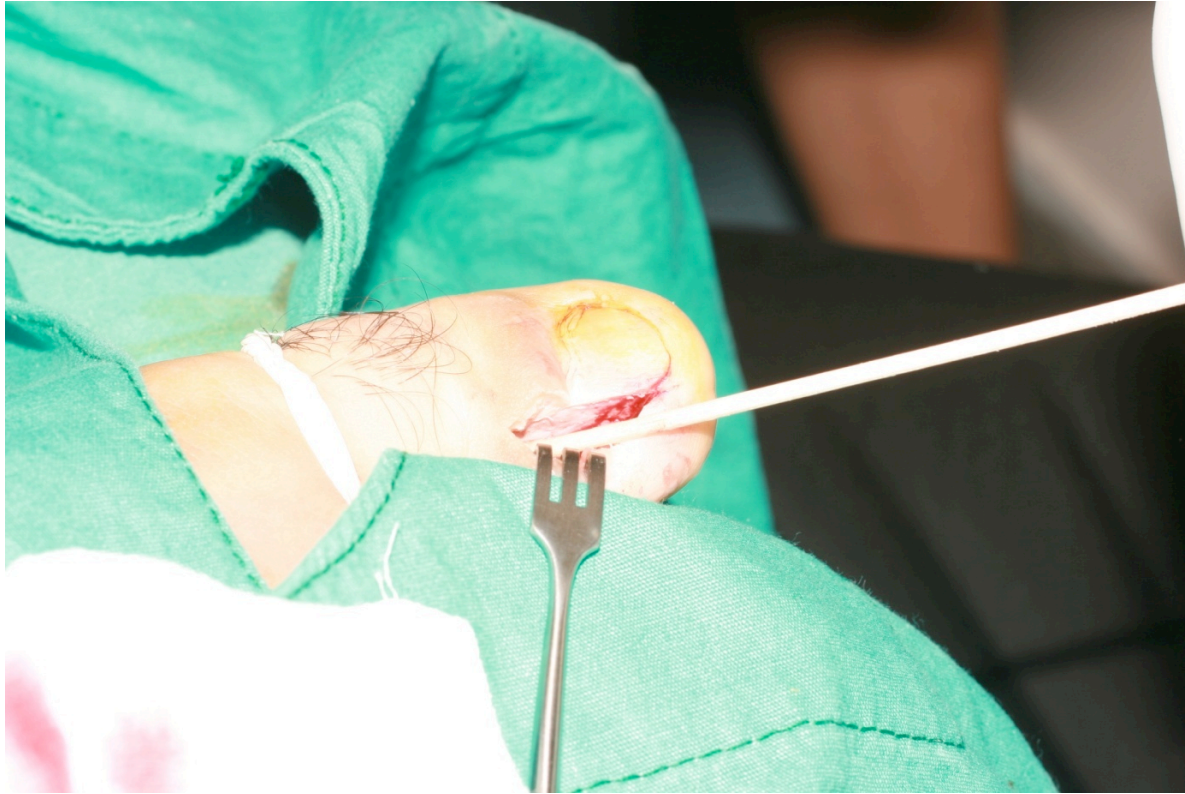
Supplemental Figure 1. After disinfection with povidone-iodine solution, digital anesthesia was administered with lidocaine hydrochloride 20 mg/mL and epinephrine hydrochloride 0.0125 mg/mL.



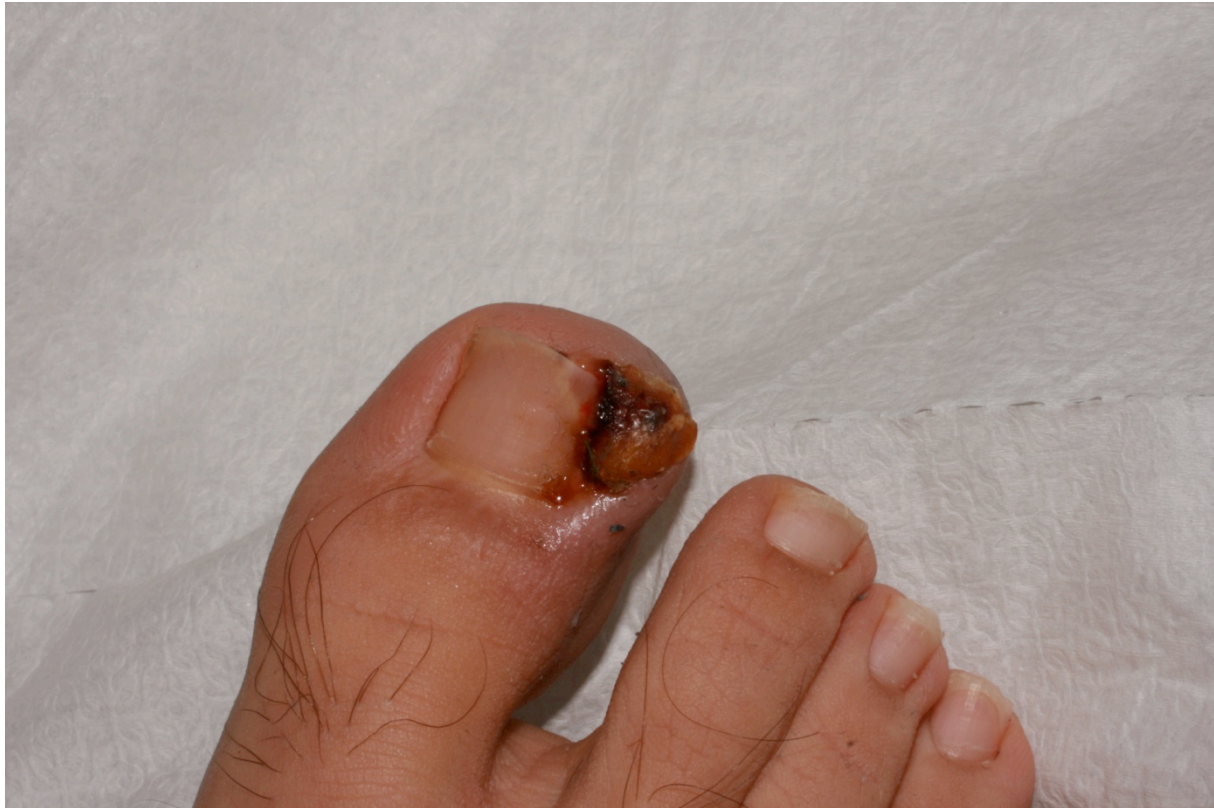Supplemental Figure 2. After removing the nail and the matrix with straight hemostatic forceps (Klemmer or Kelly), we ensured that all matrix over the distal phalanx was cleaned up by using a curette.



Supplemental Figure 3. We massaged the matrix vigorously with a cotton-tipped swab dipped in an aqueous solution of phenol 88%, with a rotation directed toward the lateral fold.



Supplemental Figure 4a. Ingrown toenail, pretreatment appearance.



Supplemental Figure 4b. One month after surgery.

